

# Gastric Leak After Laparoscopic-Sleeve Gastrectomy for Obesity

Ana Maria Burgos · Italo Braghetto · Attila Csendes ·  
Fernando Maluenda · Owen Korn · Julio Yarmuch ·  
Luis Gutierrez

Received: 17 December 2008 / Accepted: 30 April 2009  
© Springer Science + Business Media, LLC 2009

## Abstract

**Background** One of the most serious complications after laparoscopic sleeve gastrectomy (LSG) is gastric leak. Few publications exist concerning the treatment of gastric leak. We sought to determine by way of a prospective study the clinical presentation, postoperative course, and treatment of gastric leak after LSG for obesity.

**Methods** From October 2005 to August 2008, 214 patients with different degrees of obesity underwent LSG. During surgery, each patient received saline with methylene blue by way of nasogastric tube and had a drain placed. All patients underwent radiologic study with liquid barium sulphate on postoperative day 3.

**Results** Seven patients developed gastric leak. Leak in two patients (28.6%) was diagnosed by upper gastrointestinal tract (UGI) study. Two patients had type I leak (28.6%), and five patients had type II leak (71.4%). Four patients underwent reoperation. Three patients were managed medically with enteral or parenteral feeding; the drain was maintained in situ; and collections were drained by percutaneous punctions guided by computed axial tomography. Mean hospital length of stay was 28.8 days, and time to leakage closure was 43 days after surgery.

**Conclusion** Different ways exist to manage gastric leak, depending on the magnitude of the collection and the clinical repercussions. When treatment necessitates reintervention and is performed early, suture repair is more likely to be successful. Leakage closure time will vary.

**Keywords** Bariatric surgery · Gastric leak · Morbid obesity · Sleeve gastrectomy

## Introduction

The increasing prevalence of morbid obesity, as well as the fact that surgery is the only proven long-term effective treatment for this condition, has led to the search for surgical techniques that can provide adequate weight loss with the least possible morbidity and mortality.

Laparoscopic sleeve gastrectomy (LSG), a new procedure for weight loss, was initially developed by Gagner et al. and constituted the first stage of bariatric surgery for the superobese or high-risk patient [1]. It is performed after either laparoscopic biliopancreatic diversion with duodenal switch [1] or Roux-en-Y gastric bypass (RYGB) [2]. Later, LSG as a sole bariatric operation was reported in several publications [3–6]. Baltasar [4] considered it a multipurpose bariatric procedure. However, LSG can be associated with significant morbidity, and staple-line failure with dehiscence and gastric leak is one of the most severe complications.

The purpose of the present prospective study was to determine the clinical presentation, postoperative course, and treatment of gastric leak after LSG in a consecutive group of obese patients.

## Material and Methods

### Patients Studied

From October 2005 to August 2008, 214 patients with morbid obesity were included in a prospective protocol and under-

A. M. Burgos (✉) · I. Braghetto · A. Csendes · F. Maluenda ·  
O. Korn · J. Yarmuch · L. Gutierrez  
Department of Surgery, University Hospital University of Chile,  
Santos Dumont No. 999,  
Santiago, Chile  
e-mail: anamburgos@yahoo.com.mx

went LSG. Mean body mass index was  $37.8 \pm 5.0 \text{ kg/m}^2$ ; 162 (75.7%) patients were female and 52 (24.3 %) were male; and mean patient age was 36.5 years (range 14 to 68).

### Surgical Procedure

After administering 15 mm Hg pneumoperitoneum, 5 trocars are inserted: a 5-mm subxiphoid trocar serves as liver retractor; a 15-mm right upper quadrant trocar serves as working channel and is used to remove the specimen; a 10-mm supraumbilical trocar serves as optic system; a 12-mm left upper quadrant trocar serves as working channel for the ENDO GIA and gastric retraction; and a 10-mm left subcostal anterior axillary line trocar serves as another working channel. LSG is performed by dividing the greater curvature vessels using a LigaSure device (Covidien, Cincinnati, OH), beginning 2 cm proximal to the pylorus until 1 cm near the angle of His, cutting the short gastric and posterior fundic vessels. Once this maneuver is completed, a 32F or 38F bougie is introduced by the anesthesiologist into the stomach, and the surgeon advances it along the lesser curvature into the pyloric channel and duodenal bulb. An ENDO GIA stapler with 4.8-mm staples (green cartridge) is introduced through the 15-mm port, which is located at the right quadrant, to begin the division of the antrum 2 to 3 cm proximal to the pylorus. This is completed using another green cartridge up to the incisura angularis. Gastric tubulization is completed by dividing the gastric corpus straight to the angle of His angle, applying three to four blue cartridges of the 3.5-mm ENDO GIA stapler. Reinforcement with absorbable sutures (Maxon 2-0 or 3-0) is performed over the mechanical closure, leaving a small gastric tubular pouch of 60 to 80 ml capacity. This is controlled by administration of methylene blue by way of a nasogastric tube, which is placed after the bougie is removed, for the purpose of protecting against suture-line leak and aiding the evaluation of gastric capacity. To determine leakage, we transiently block flow into the duodenum with a long intestinal forceps at the pyloric channel. The resected specimen, which is removed easily through the 15-mm port at the right upper abdominal quadrant, is sent for histological analysis. Routine liver biopsy is also performed. One Silastic drain is always left at side of the gastric suture line. No leaks were observed during surgery in any patient.

### Clinical Evaluation

Clinical symptoms (e.g., pain, discomfort) and signs (e.g., fever, abdominal distension, tachycardia, tachypnea) were recorded for all patients every 6 hours.

### Radiologic Surveillance

In all patients, upper gastrointestinal tract (UGI) radiography was performed on postoperative day (POD) 3 using liquid barium sulphate but not Gastrografin or Hypaque. While standing, the patient swallows 20 ml barium, and the characteristics of the tubular stomach (i.e., size, emptying, and presence or absence of leak or stricture) are evaluated. Six different radiographs are taken with the patient situated in several different positions. Previous reports have shown that even a type I leak (small, localized, and asymptomatic) can be easily diagnosed with barium sulphate but not with liquid contrast media [7].

### Definition of Terms

One “standard” definition of anastomotic leak has been proposed by the UK Surgical Infection Study Group for use in clinical audits and to form the basis for meaningful comparisons. Leak was defined as “the leak of luminal contents from a surgical join between two hollow viscera.” A leak may also represent a gastrointestinal leak in a suture line around the organ. Luminal contents may emerge through the wound or at the drain site, or they may collect near the anastomosis [8].

### Definition of Leaks

Based on the time when leaks appear, they have been previously classified and published [9, 10] as follows: early (leaks appearing 1 to 3 days after surgery), intermediate (leaks appearing 4 to 7 days after surgery), and late (leaks appearing  $\geq 8$  days after surgery).

### Classification of Leak

In accordance with UGI contrast studies, gastric leaks have been classified as follows:

1. Type I or subclinical: This corresponds to local leakage, with no spillage or dissemination, through a fistulous track to the pleural or abdominal cavity or the appearance of contrast material in any abdominal drain.
2. Type II or clinical: This corresponds to leakage with great dissemination or diffusion to the pleural or abdominal cavity, by way of an irregular pathway, with appearance of contrast medium in any of the abdominal drains [7].

The location, time of appearance, and closure of all leaks were carefully recorded.

**Table 1** Clinical presentation of patients with gastric leak

Symptoms, signs, and laboratory examinations	Mean $\pm$ SD (range)	No. (%) of patients with gastric leak (n=7)
Abdominal pain		6 (85.7)
Fever ( $^{\circ}$ C; normal $<37$ )	38.5 $\pm$ 0.7 (37.7–40.0)	6 (85.7)
Tachycardia (bpm; normal $<80$ )	117 $\pm$ 8.2 (110–129)	4 (57.1)
Tachypnea (breaths per minute; normal $<18$ )	24	1 (14.2)
Increased WBC count (normal $<10.000$ leukocytes/mm <sup>3</sup> )	17.650 $\pm$ 3.823 (14.000–22.300)	4 (57.1)
Increased CRP (mg/l; normal $<10$ )	252 $\pm$ 150 (69–547)	7 (100)

### Statistical Analysis

Data are expressed as mean  $\pm$  SD.

### Results

Among the 214 patients who underwent LSG, 7 developed gastric leak (3.3%). These patients comprised 4 women (57.1%) and 3 men (42.9%), with a mean age of 38 $\pm$ 16.2 years (range 17 to 64). From a clinical perspective, patients with gastric leak presented with abdominal pain, fever, tachycardia, tachypnea, and increased white blood cell (WBC) and C-reactive protein (CRP) levels (Table 1). Abdominal pain was localized in 3 patients at the epigastric; it was widespread in 2 patients; and it was located at the hypogastric and right flank, respectively, in 2 patients. Table 2 lists the relation between time of leak detection and symptomatology [9, 10]. The earliest symptom was tachycardia in patients with early leak, whereas fever was the earliest symptom in patients with intermediate and late leak. Gastric leak was diagnosed at mean POD 8 $\pm$ 6.1 (range POD 2 to 20). No patient died.

Fluoroscopy evidenced the leak in two patients (28.6%). UGI radiography with barium on POD 3 was initially negative for leak in five patients who presented with leak at the POD 5 or greater. Only posterior radiologic studies

using computed axial tomography (CAT) and UGI contrast confirmed the presence of leak involving suture line in these five patients.

Radiologic scans showed gastric leak located at the proximal third of great curve in six patients (85.7%) and at the distal third in one patient (14.3%) (Figs. 1 and 2). Two patients had type I gastric leak (28.6%), and five patients had (71.4%) had type II gastric leak. The first patient with type I leak initially had a normal postoperative course. However, on POD 8, she suddenly developed unexplained fever lasting 1 day, with increased WBC count and mild abdominal pain. The patient was rehospitalized, and evaluation using CAT and UGI with barium sulphate confirmed the presence of a leak. Treatment was to withhold oral food and administration of intravenous fluids and antibiotics. Her fever and abdominal pain resolved, and she was discharged asymptomatic on POD 18. The second patient with type I leak presented a leak of soup through the drain route, which was reinserted on POD 20, and radiologic evaluation confirmed a minimal leak in front of the incisura angularis region.

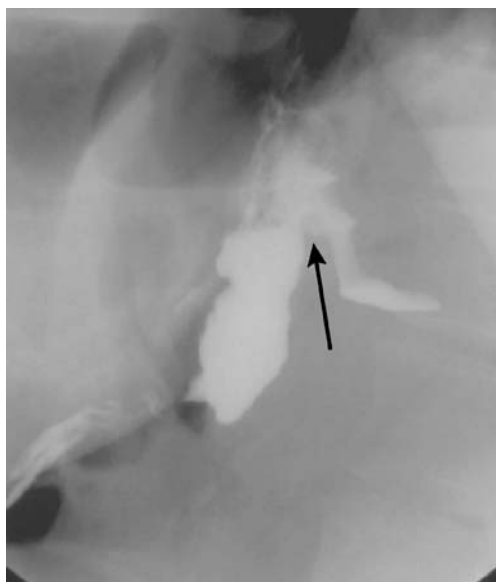
Five patients with type II leak had a completely different postoperative course. They developed abdominal pain, fever, tachycardia, tachypnea, increased WBC and CRP levels with obvious sepsis at a different range of PODs (range POD 1 to 20). In three patients, radiologic scans showed diffuse dissemination of barium, even in the pelvis,

**Table 2** Postoperative diagnostic period of leak and symptoms

Presentation of leak	No. of patients (%)	POD diagnosis	POD tachycardia (n=4)	POD fever (n=6)	POD abdominal pain (n=7)
Early (POD $\leq$ 3)	1 (14.3)	2	–	–	2
	1 (14.3)	3	1*	2	1
Intermediate (POD 4–7)	1 (14.3)	5	4	4	4
	1 (14.3)	6	7	5*	9
Late ( $\geq$ POD 8)	2 (28.5)	10/10	12/–	10/8*	6/10
	1 (14.3)	22	–	22	22

Relation between presentation time of leak (i.e., Csendes classification) [9, 10] and symptomatology.

\*Earliest symptom.



**Fig. 1** Gastric leak localized at the proximal third

whereas the leak was detected by fluoroscopy in one patient in whom daily output of the abdominal drain had increased. All four patients underwent reoperation (Table 3). The last patient was treated conservatively with parenteral feeding, administration of antibiotics, and percutaneous reinstallation of drainage. UGI demonstrated complete healing of gastric leak at a mean of 43 days after surgery (range POD 2 to 125). Hospital length of stay (LOS) was  $28.8 \pm 15$  days (range 12 to 54), with 4 days being the most common LOS in patients without leak.

## Discussion

LSG is a new option being used in the treatment of morbid obesity. Benefits of LSG include low rate of complications, avoidance of foreign material, maintenance of normal gastrointestinal continuity, absence of malabsorption, and ability to perform it concomitantly with other procedures.

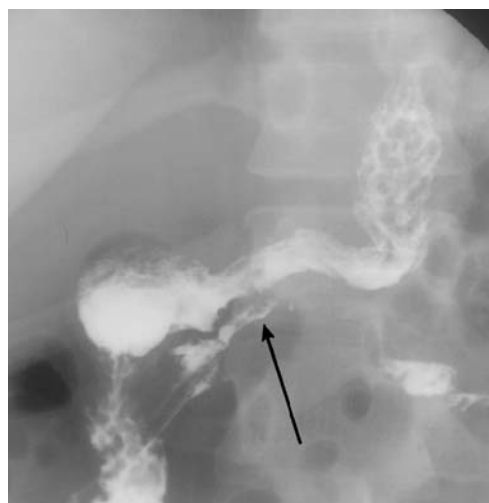The two most common surgical complications after bariatric operations are staple-line bleeding and anastomotic leak. Gastric leak is secondary to alterations in the normal acute healing process. Local risk factors include unsatisfactory healing of the suture line, inadequate blood supply, infection, and inadequate oxygenation with subsequent ischemia. We believe that leaks are not a consequence of staple-line failure or dehiscence; rather, we believe that the presence of gastric-wall heat ischemia near the staple line, which may be caused by dissection of the greater curvature using electrocautery or the LigaSure device, may be a major cause of leak. Both methods can result long-term effects, and therefore the production of the leak may be an initial error in surgical technique, by which intraluminal

pressure exceeds the strength of the tissue and the staple line, resulting in a leak. Classic ischemic leaks have been reported to occur 5 to 7 days after surgery when wound healing is between the inflammatory and fibrosis phases [11, 12]. Extraluminal gastric leak can result in cutaneous fistula, peritonitis, abscess, sepsis, organ failure, and death [13].

The incidence of gastric leak in several reports concerning LSG is listed in Table 4 [14–21]. The reported values vary from 0.7% to 5.0% (mean 2.3%). Our leak rate of 3.3% is consistent with that reported by other studies in the literature [16]. Csendes et al. [22] reported a leak incidence of 1.7% after open gastric bypass and leak rate of 4.3% after laparoscopic gastric bypass.

The clinical presentation of postoperative gastric leak ranges from asymptomatic radiographic finding to peritonitis, septic shock, multisystem organ failure, and death. Hamilton et al. [23] described 9 leaks in 210 patients who underwent laparoscopic RYGB. They evaluated various clinical signs and concluded that evidence of respiratory distress and tachycardia  $>120$  beats per minute (bpm) may be the most useful clinical indicator of leak. In our study, tachycardia was an early symptom in patients with early leak. We also observed that patients with leak presented symptomatology before the leak was detected. Hamoui et al. [15], reported 1 death, caused by gastric leak, in the postoperative month 2 in the LSG group. There was no mortality in our series.

Carucci et al. [13] found 48 leaks in 904 patients after RYGB. In 12 patients, the initial UGI studies did not show leak, but leak was diagnosed with follow-up UGI studies performed 4 to 28 days after the initial surgery. In our patients, UGI was initially negative for leak in 5 patients with intermediate or late leak because the series were performed at POD 3, whereas leak appeared  $\geq 5$  days after



**Fig. 2** Gastric leak localized at the distal third

**Table 3** Reoperation in patients with gastric leak

Patients undergoing reoperation (n=4)	Reoperation time (POD)	Reoperation type	Resuture outcome
Case no. 1	12	Laparotomy, lavage, and drainage	–
Case no. 2	3	Laparoscopy, lavage, drainage, and resuture of leak	Failure
Case no. 3	8	Laparoscopy, lavage, and drainage	–
Case no. 4	2	Laparoscopy, lavage, drainage, and resuture of	Satisfactory

surgery. This is a crucial finding. Investigators who perform radiologic studies at POD 1, when no leak is present, give surgeons a false sense of security.

In the majority of our patients (85.7%), leak was located at the left of proximal third of the “new great curve” or “middle curve.” The antral area was a rare site of leak; however, if division is begun close to the pylorus, this thick area can crack and predispose to leak. Several studies have reported leak after LSG; however, they do not mention leak at the suture line. Melissas et al. [19] reported one patient who developed a leak at the upper part of the excision line, and Tucker et al. [21] similarly reported one patient who developed a leak that presented high on the greater curve, just distal to the angle of His. They suggested leaving a narrow cuff of tissue at the most superior aspect of the greater curve, just below the angle of His, which should be imbricated with a running 2/0 silk suture.

Surgical technique is of significant importance to successful surgical outcome. Gentle handling of tissues, optimal staple-line formation, and ensuring adequate haemostasis without causing tissue damage from electro-bistury are important. Csendes et al. [9, 10] reported that three types of leaks may develop after bariatric operations: (1) early leak, which appears 1 to 3 days after surgery and are usually secondary to technical surgical problems; (2) intermediate leaks, which appear 4 to 7 days after surgery; and (3) late leaks, which appear 8 to  $\geq 10$  days after surgery. We had two patients with early leak who needed early reoperation. We observed that if reoperation and primary

repair of the leak are performed early after surgery (i.e., POD 2), when the defect can be easily identified and the local tissues are not severely inflamed, resuturing is favorable (e.g., in one of our patients). In another patient, resuture (POD 3) failed, and the gastric leak closed spontaneously on POD 125. Otherwise, in patients with longstanding leaks, closure of the defect may not be possible because there may be dense inflammatory changes and intra-abdominal fluid sequestration around the leak. In such cases, lavage and wide drainage is the best option (Table 3). If not recognized early and treated promptly, postoperative leak is a potentially lethal complication of bariatric surgery. It is necessary to emphasize the importance of early diagnosis and treatment of gastric leak because it can be treated with an appropriate surgical procedure, and a worst-case scenario can be avoided.

In the First International Consensus Summit for Sleeve Gastrectomy [24], reported treatment of leak included early oversewing, drainage (CAT or open), endoscopic clipping, and persisting fistulas requiring fibrin glue, stents, Roux-loop, and even total gastrectomy. In our patients, gastric leak closed at a mean of 43.7 days after surgery, which is a longer period than reported by Csendes et al. among patients undergoing gastric bypass, in whom the leaks closed spontaneously at a mean of 30 days after surgery [9]. We believe that an explanation for prolonged closure observed in our patients compared with others undergoing such techniques as gastric bypass could be the presence of increased intragastric pressure in the sleeved stomach (mean  $43 \pm 8$  mm Hg), whereas mean intragastric pressure in a normal stomach is  $34 \pm 6$  mm Hg [25].

In addition, prolonged hospital LOS is a common consequence of gastric leak. Whereas the average hospital LOS after routine LSG is 3 to 4 days, hospital LOS increased to an average of 28.8 days in the setting of gastric leak in our study. Others studies have reported a mean hospital LOS between 3.2 and 6 days [15, 16].

Some preventive measures should be taken to prevent leak: careful patient selection, adequate surgical procedure, gentle handling of tissues, careful suturing, avoidance of distal strictures, and careful management of electrocautery and the LigaSure device, especially the latter because we are convinced that the most important factor for leak pathogenesis is thermal damage.

**Table 4** Incidence of gastric leak after LSG in reported series

Author	Year	No. of patients	Leak rate (%)
Han et al. [14]	2005	130	0.7
Hamoui et al. [15]	2006	118	0.8
Roa et al. [16]	2006	30	3.3
Cottam et al. [17]	2006	126	1.5
Weiner et al. [18]	2007	120	2.5
Melissas et al. [19]	2007	19	5.3
Felberbauer et al. [20]	2008	126	2.3
Tucker et al. [21]	2008	148	0.7
Present series	2008	214	3.3

In conclusion, there are different ways to manage gastric leak, depending on the magnitude of fluid collection and clinical repercussions. Early diagnosis is key to adequate treatment with drainage or reintervention. When treatment requires reintervention, and if reoperation is performed early, suture repair is more likely to be successful. Leakage closure time will vary.

## References

- Gagner M, Chu CA, Quinn T, et al. Two-stage laparoscopic biliopancreatic diversion with duodenal switch: an alternative approach to super-super morbid obesity. *Sur Endosc* [abstract]. 2003;16:S069.
- Regan JP, Inabnet WB, Gagner M, et al. Early experience with two-staged laparoscopic Roux-en-Y gastric bypass as an alternative in the super-super obese patient. *Obes Surg*. 2003;13:861–4.
- Mognol P, Chosidow D, Marmuse JP. Laparoscopic sleeve gastrectomy as an initial bariatric operation for high-risk patients: initial results in 10 patients. *Obes Surg*. 2005;15:1030–3.
- Baltasar A, Serra C, Perez N, et al. Laparoscopic sleeve gastrectomy; a multi-purpose bariatric operation. *Obes Surg*. 2005;15:1124–8.
- Baltasar A, Bou R, Bengochea M, et al. Mil operaciones bariátricas. *Cir Esp*. 2006;79:349–55.
- Braghetto I, Korn O, Valladares H, et al. Laparoscopic sleeve gastrectomy: surgical technique, indications and clinical results. *Obes Surg*. 2007;17:1442–50.
- Csendes A, Diaz JC, Burdiles P, et al. Classification and treatment of anastomotic leakage after extended total gastrectomy in gastric carcinoma. *Hepatogastroenterology*. 1990;37:174–7.
- Bruce J, Krukowski ZH, Al-Khairi G, et al. Systematic review of the definition and measurement of anastomotic leak after gastrointestinal surgery. *Br J Surg*. 2001;88:1157–68.
- Csendes A, Burdiles P, Burgos AM, et al. Conservative management of anastomotic leaks after 557 open gastric bypasses. *Obes Surg*. 2005;15:1252–6.
- Csendes A. Conservative management of anastomotic leaks. *Obes Surg*. 2006;16:375–6.
- Baker RS, Foote J, Kemmeter P, et al. The science of stapling and leaks. *Obes Surg*. 2004;14:1290–4.
- Dubay DA, Franz MG. Acute wound healing: the biology of acute wound failure. *Surg Clin North Am*. 2003;3:463–81.
- Carucci LR, Turner MA, Conklin RC, et al. RYGB surgery for morbid obesity: evaluation of postoperative extraluminal leaks with upper gastrointestinal series. *Radiology*. 2006;238:119–27.
- Han SM, Kim WW, Oh J. Results of laparoscopic sleeve gastrectomy at 1 year in morbidly obese Korean patients. *Obes Surg*. 2005;15:1469–75.
- Hamoui N, Anthone GJ, Kaufman HS, et al. Sleeve gastrectomy in the high-risk patient. *Obes Surg*. 2006;16:1445–9.
- Roa PE, Kaidar-Person O, Pinto D, et al. Laparoscopic sleeve gastrectomy as treatment for morbid obesity: technique and short-term outcome. *Obes Surg*. 2006;16:1323–6.
- Cottam D, Qureshi FG, Mattar SG, et al. Laparoscopic sleeve gastrectomy as an initial weight-loss procedure for high-risk patients with morbid obesity. *Surg Endosc*. 2006;20:859–63.
- Weiner RA, Weiner S, Pomhoff I, et al. Laparoscopic sleeve gastrectomy—influence of sleeve size and resected gastric volume. *Obes Surg*. 2007;17:1297–305.
- Melissas J, Koukouraki S, Askoxylakis J, et al. Sleeve gastrectomy—a restrictive procedure? *Obes Surg*. 2007;17:57–62.
- Felberbauer FX, Langer F, Shakeri-Manesch S, et al. Laparoscopic sleeve gastrectomy as an isolated bariatric procedure: intermediate-term results from a large series in three Austrian centers. *Obes Surg*. 2008;18:814–8.
- Tucker ON, Szomstein S, Rosenthal RJ. Indications for sleeve gastrectomy as a primary procedure for weight loss in the morbidly obese. *J Gastrointest Surg*. 2008;12:662–7.
- Csendes A, Maluenda F. Morbimortality of bariatric surgery. Chilean experience in 10 surgical centres. *Rev Chil Cir*. 2006;58:208–12.
- Hamilton EC, Sims TL, Hamilton TT, et al. Clinical predictors of leak after laparoscopic Roux-en-Y gastric bypass for morbid obesity. *Surg Endosc*. 2003;17:679–84.
- Deitel M, Crosby RD, Gagner M. The First International Consensus Summit for Sleeve Gastrectomy (SG), New York City, October 25–27, 2007. *Obes Surg*. 2008;18:487–96.
- Yehoshua RT, Eidelman LA, Stein M, et al. Laparoscopic sleeve gastrectomy—Volume and pressure assessment. *Obes Surg*. 2008;18:1083–8.